

Tympanoplasty with Boomerang-Shaped Chondoperichondrial Graft: Long-Term Results

ABSTRACT

Background: we aimed in this study to evaluate and present the long-term results of type 1 tympanoplasty patients who were operated by using boomerang-shaped chondoperichondrial graft.

Methods: One hundred thirty-eight patients who underwent primary type 1 tympanoplasty, had tragal cartilage removal, and used boomerang-shaped chondoperichondrial graft between September 2010 and March 2014 were examined and 62 patients who could be reached through their contact information and had complete preoperative records were included in this retrospective study. Audiological and otomicroscopic examinations were performed on the patients who were contacted. The condition of the graft, preoperative and postoperative air-bone gap values, and retraction findings on graft were noted. These findings were compared with preoperative notes.

Results: The preoperative mean air-bone gap value of the patients was 23.690 ± 1.036 decibels. As a result of the audiological examination performed at the last follow-up of these patients, the mean air-bone gap values of at least fifth year postoperatively were measured as 10.6 ± 0.791 decibels ($P < .0001$). The control periods were between 122 and 60 months and the mean control period was 73.03 months. Perforation was detected in 6 (9.7%) patients on otomicroscopic examination.

Conclusion: Considering the long-term results, we think that this grafting technique of tympanoplasty has adequate and satisfactory results.

Keywords: Tympanoplasty, boomerang, chondoperichondrial graft



INTRODUCTION

The use of full-thickness skin as a graft material for tympanic membrane perforation repair in tympanoplasty type 1 operations was first described by Berthold, and in the following period this method was developed by using different graft materials and different surgical approaches. Temporal muscle fascia, perichondrium, and cartilage grafts are the most commonly used graft materials today. Graft success in tympanoplasty using these graft materials varies between 78% and 92%.¹ Cartilage is the most prominently used material. Its stability, long-term positive results, and ease of obtaining and application make cartilage grafting preferable. Many cartilage grafting techniques have been described from past to present. Tos is one of the prominent experts in this sense having described many techniques using conchal and tragal cartilage and is known as an irreplaceable surgeon in this field.^{2,3}

Cartilage has been used in the form of islands, palisades, and in other ways, and there are many studies in the literature on success rates.³ We described the boomerang-shaped chondoperichondrial grafting (BSCPG) technique as a new grafting technique 8 years ago. We reported the anatomical and functional results of 99 patients who underwent BSCPG at the end of the first year in which we used tragal cartilage and left only the boomerang-shaped cartilage in the anterior and lower parts⁴ (Figure 1).

In this study, we aimed to evaluate and present the long-term results of type 1 tympanoplasty patients who were operated by using this graft type.

Tarık Yağcı ^{ID}¹
Rıza Dündar ^{ID}²
Ahmet Yükkaldıran ^{ID}³

¹Department of Otorhinology, Bilecik Training and Research Hospital, Bilecik, Turkey

²Department of Otorhinolaryngology, Bilecik Şeyh Edebalı University Faculty of Medicine, Bilecik, Turkey

³Department of Otorhinolaryngology, Şanlıurfa Training and Research Hospital, Şanlıurfa, Turkey

Cite this article as: Yağcı T, Dündar R, Yükkaldıran A. Tympanoplasty with boomerang-shaped chondoperichondrial graft: long-term results. *ENT Updates*. 2022;12(1):63-66.

Corresponding author:
Rıza Dündar
Email: dundarkbb2@gmail.com
Received: September 11, 2021
Accepted: January 6, 2022



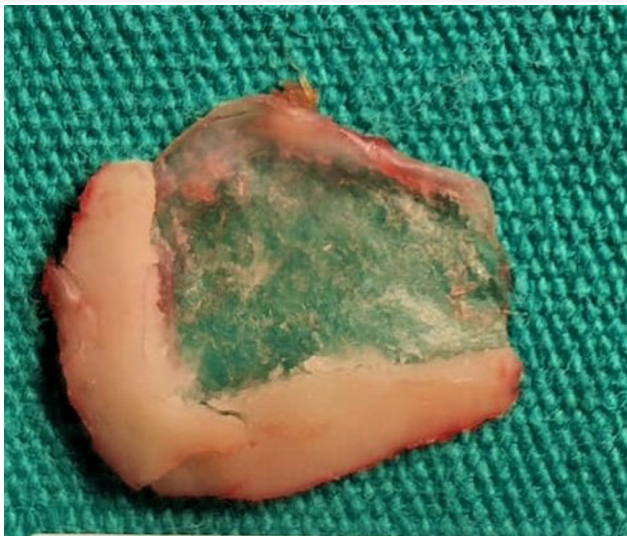


Figure 1. Boomerang-shaped chondroperichondrial graft.

METHODS

This study was designed as a retrospective study and was approved by the non-interventional clinical research ethics committee Bilecik Şeyh Edebali University (04.07.2021 3304). This study was conducted according to the rules of the Helsinki Declaration.⁵

Patients

One hundred thirty-eight patients who underwent primary type 1 tympanoplasty by the same surgeon, had tragal cartilage removal, and BSCPG between September 2010 and March 2014 were examined and 62 patients who could be reached through their contact information and had complete preoperative records were included in this retrospective study. Patients with a history of revision surgery, perioperative ossicular chain pathology, and cholesteatoma were excluded from the study.

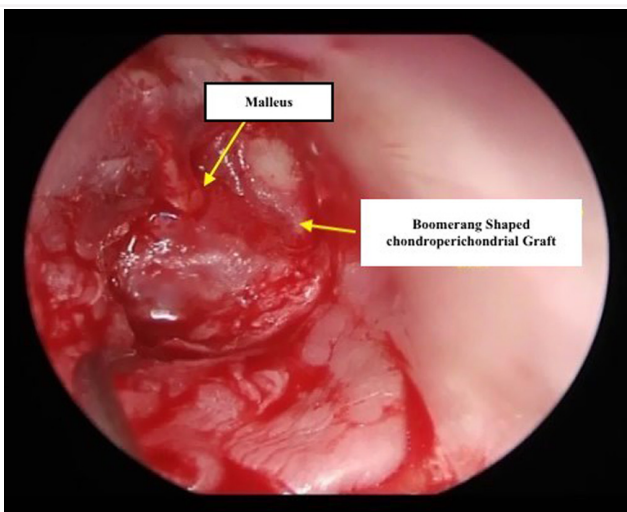


Figure 2. Position of the boomerang-shaped chondroperichondrial graft (medial to malleus and annulus).

Audiological and otomicroscopic examinations were performed on the patients who were contacted. The condition of the graft, preoperative and postoperative air-bone gap values, and retraction findings on graft were noted. These findings were compared with preoperative notes.

All patients were operated on under general anesthesia and using a microscope. The endaural approach was preferred. Grafts were implanted to the patients by using the underlay medial tympanoplasty technique (Figure 2).

Audiometric Evaluation

Preoperative and postoperative audiograms of all patients were evaluated as per the American Academy of Otolaryngology-Head and Neck Surgery Committee on Hearing and Equilibrium guidelines. Air and bone conduction hearing thresholds were determined by performing pure tone audiometry tests (0.25-8.0 kHz). Mean hearing thresholds and air-bone gaps were calculated considering 0.5, 1.0, and 2.0 kHz values.

Statistical Analysis

GraphPad Prism 6.01 (GraphPad, California, USA) was used for the statistical analysis and plotting of the graphs. The results were expressed as means \pm standard error of the mean and the data were analyzed with unpaired *t*-test with Welch's correction. The degree of significance was denoted as 1-tailed $P \leq .0001^{****}$.

RESULTS

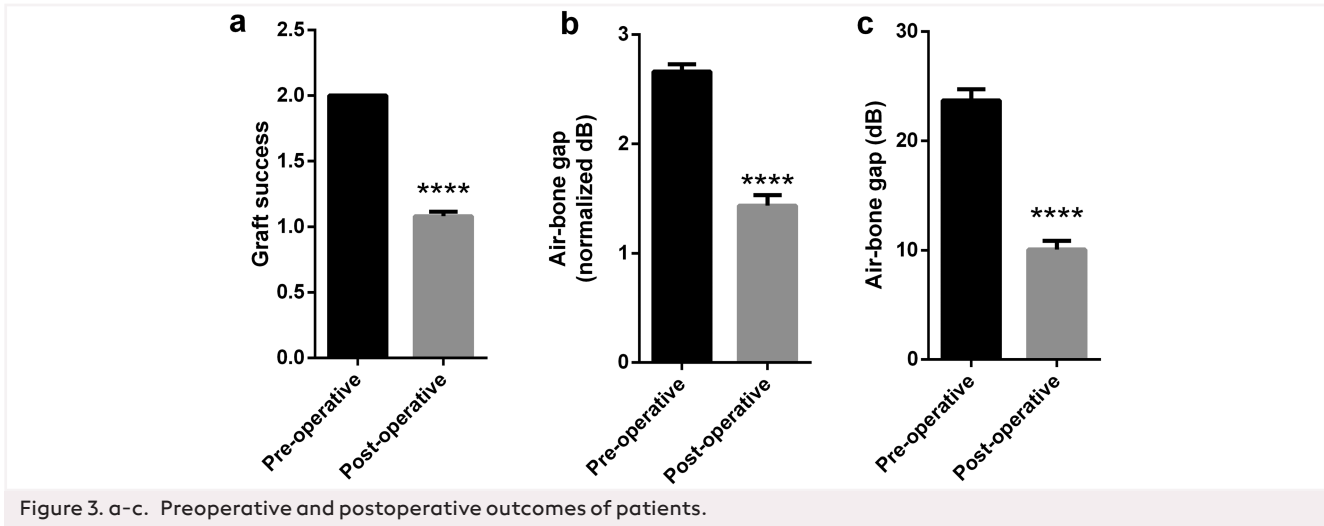
Twenty-seven (43.5%) of 62 patients were female and 35 (56.5%) were male. The right ear was operated on in 29 (46.7%) patients and the left ear in 33 (53.3%) patients. The age ranges were between 21 and 65 years and the mean age was 35.22 years.

The control periods were between 122 and 60 months and the mean control period was 73.03 months. Perforation was detected in 6 (9.7%) patients on otomicroscopic examination. Three of these perforations were in the central quadrant and 3 of them were in the posterosuperior quadrant. Graft success rate was 90.3%. Grade 1 retraction was observed in the posterosuperior area in 5 (8.1%) of the patients according to the Sade classification.⁶ No lateralized graft was detected.

The preoperative mean air-bone gap value of the patients was 23.690 ± 1.036 decibels. As a result of the audiological examination performed at the last follow-up of these patients, the mean air-bone gap values of at least fifth year postoperatively were measured as 10.6 ± 0.791 decibels. In the preoperative audiological evaluation of these patients, Air Bone Gap (ABG) was 10 dB and below in 2, 10-20 dB in 17 patients, and 20 dB and above in 43 patients. These values were found to be 10 dB in 45 of them, between 10 and 20 dB in 7 of them, and 20 dB and above in 10 of them in the long-term postoperative period, respectively. When these results were evaluated statistically, the result was significant ($P < .0001$) (Figure 3, Table 1).

DISCUSSION

In this study, we tried to give information about the long-term results of BSCPG, which we have been applying to our tympanoplasty patients for about 10 years. We first published this grafting technique 8 years ago with the postoperative



12th-month results.⁴ In this study, which we conducted to determine how these satisfactory results are in the long-term, we can say that we have achieved very good results when the graft success and hearing function values were examined. Graft success rate was 90.3%, and it was similar to other grafting techniques reported in the literature. The effect on hearing function was evaluated over the improvement in air-bone gap values. The improvement in these values was obvious and was at a satisfactory level.

Also, in the long-term analysis of graft lateralization and medialization in these patients, since we performed medial grafting, no lateralized graft was detected in this technique, and no postoperative cholesteatoma was encountered. Only in the long-term, 5 patients had medialization in the postero-superior quadrant, which was grade 1 according to the Sade classification.

Many studies and results have been reported on tympanic membrane grafting materials and their use in different ways. In some studies using cartilage, although the success of the graft was very good, it has been reported that the hearing function was

not very satisfactory compared to other graft materials, such as the temporal muscle fascia.⁷ De sate et al⁸ reported the anatomical and functional results of type 1 tympanoplasty in patients with subtotal central perforation of the tympanic membrane. Two types of graft materials were used in this study. The study included a total of 106 patients; they used cartilage grafting using tragal cartilage in 53 patients and temporal muscle fascia in the other 53 patients. Postoperative 6 and 12 months audiometry results were evaluated for both groups and the results were similar. They reported that anatomical results were better in patients who underwent cartilage grafting, especially at the end of the first year.

Another problem in tympanoplasty operations in which cartilage grafts are used is the missed out cholesteatoma cases due to the cartilage thickness and inadequate middle ear visualization during the follow-ups. Gerber⁹ stated that the closure of the mesotympanum with full-thickness cartilage also hides the findings of cholesteatoma formation. For this purpose, we think that in this technique we designed, the central and posterior graft area consists only of the perichondrium and will not cause such a problem.

Shakya et al¹⁰ reported that anatomical and functional results in patients who had temporal muscle fascia graft in long-term follow-up were worse than patients who had a cartilage graft. Neumann et al¹¹ published 10-year results in their study on 29 patients and reported a graft success rate of 100%. Gaslin et al¹², on the other hand, performed cartilage tympanoplasty on 40 pediatric patients and reported 2-year control results whereas the graft success rate was 95.2%.

In this study, we compiled the average 6-year results of our patients after BSCPG, which we described in 2013. Sixty-two patients were reached, and the anatomical and functional results of these patients were evaluated. In the preoperative audiological evaluation of these patients, ABG was 10 dB and below in 2, 10-20 dB in 17 patients, and 20 dB and above in 43 patients. These values were 10 dB in 45 of them, between 10 and 20 dB in 7, and 20 dB and above in 10 patients in the

Table 1. Preoperative and Postoperative Air-Bone Gap and Graft Success of Patients

Parameters	Study Groups	
	Preoperative (N=62)	Postoperative (N=62)
Graft success	2.000±0.000	1.081±0.034****
Air-bone gap (normalized dB)	2.661±0.068	1.435±0.096****
Air-bone gap (raw dB)	23.690±1.036	10.60±0.791****

Graft success: 2: perforation, 1: no perforation. The air-bone gaps ≤10 dB, 11-20 dB, and ≥20 dB was normalized to 1, 2, and 3, respectively. The unpaired t-test with Welch's correction was used to compare the preoperative and postoperative patient groups (****P ≤ .0001).

long-term postoperative period. Long-term graft success was 90.3% in these patients.

Our study has limitations since we reached a limited number of patients. However, we tried to reach as much as possible, and we think we have reached a number that can form an idea about the long-term results of a new technique.

In conclusion, BSCPG, which we define as a chondroperichondrial graft when both its design and location are considered, proves the fact that it creates serious support with cartilage in the anterior and lower part of the tympanic membrane area, prevents the graft movement that is common in these regions, leading to positive anatomical results, and creates a vibration field close to the normal tympanic membrane thickness with the perichondrial part. We think that it has acceptable long-term results from a functional point of view.

Ethics Committee Approval: Ethics committee approval was received from the Ethics Committee of Bilecik Şeyh Edebali University (04.07.2021; 3304).

Informed Consent: Informed consent was obtained from the all participants who participated in this study.

Peer review: Externally peer-reviewed.

Author Contributions: R.D., T.Y., A.Y.; Design - R.D., T.Y., A.Y.; Supervision - R.D., T.Y., A.Y.; Resource - R.D., T.Y., A.Y.; Materials - T.Y., R.D., A.Y.; Data Collection and/or Processing - T.Y., R.D., A.Y.; Analysis and/or Interpretation - T.Y., R.D., A.Y.; Literature Search - T.Y., R.D., A.Y.; Writing - T.Y., R.D., A.Y.; Critical Reviews - T.Y., R.D., A.Y.

Conflict of Interest: The authors have no conflicts of interest to declare.

Financial Disclosure: The authors declared that this study has received no financial support.

REFERENCES

1. Kalcioğlu MT, Fırat Y, Selimoğlu E. Cartilage tympanoplasty with island technique; a comparison with the temporalis muscle fascia technique. *Int Adv Otol.* 2009;5(1):45-50.
2. Dornhoffer J. Cartilage tympanoplasty: indications, techniques, and outcomes in a 1,000 patient series. *Laryngoscope.* 2003;113(11):1844-1856. [\[CrossRef\]](#).
3. Tos M. Cartilage tympanoplasty methods: proposal of a classification. *Otolaryngol Head Neck Surg.* 2008;139(6):747-758. [\[CrossRef\]](#)
4. Dündar R, Soy FK, Kulduk E, Muluk NB, Cingi C. A new grafting technique for tympanoplasty: tympanoplasty with a boomerang-shaped chondroperichondrial graft (TwBSCPG). *Eur Arch Otorhinolaryngol.* 2014;271(10):2687-2694. [\[CrossRef\]](#)
5. 52nd WMA General Assembly World Medical Association Declaration of Helsinki: ethical principles for medical research involving human subjects. *JAMA.* 2000;284(1):3043-3049.
6. Sade J. The atelectatic ear. In: Sade J, ed. *Secretary Otitis Media and Its Sequelae.* London: Churchill Livingstone; 1979:64-68.
7. Poe DS, Gadre AK. Cartilage tympanoplasty for management of retraction pockets and cholesteatomas. *Laryngoscope.* 1993;103(6):614-618. [\[CrossRef\]](#)
8. De Seta E, De Seta D, Covelli E, Viccaro M, Filippo R. Type I tympanoplasty with island chondro-perichondrial tragal graft: the preferred technique? *J Laryngol Otol.* 2013;127(4):354-358. [\[CrossRef\]](#)
9. Gerber MJ, Mason JC, Lambert PR. Hearing results after primary cartilage tympanoplasty. *Laryngoscope.* 2000;110(12):1994-1999. [\[CrossRef\]](#)
10. Shakya D, Nepal A. Long-term results of type I tympanoplasty with perichondrium reinforced cartilage palisade vs temporalis fascia for large perforations: a retrospective study. *J Otol.* 2021;16(1):12-17. [\[CrossRef\]](#)
11. Neumann A, Kevenhoerster K, Gostian AO. Long-term results of palisade cartilage tympanoplasty. *Otol Neurotol.* 2010;31(6):936-939. [\[CrossRef\]](#)
12. Gaslin M, O'Reilly RC, Morlet T, McCormick M. Pediatric cartilage interleave tympanoplasty. *Otolaryngol Head Neck Surg.* 2007;137(2):284-288. [\[CrossRef\]](#)